



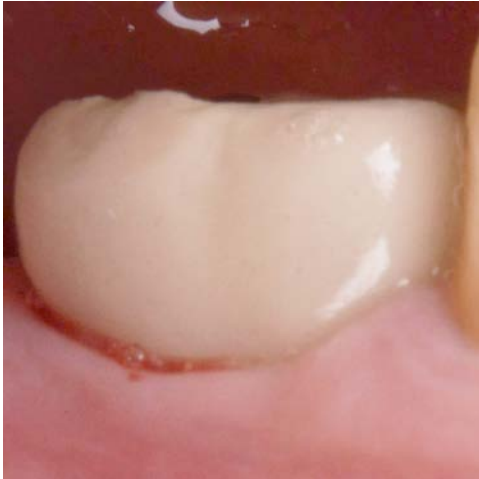Implant removal due to peri-implantitis with simultaneous ridge augmentation

Patient History

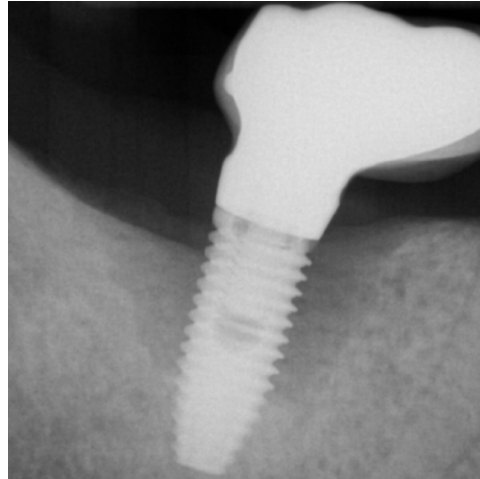
Patient suffered from an advanced peri-implantitis with bone loss occurring all around the implant, requiring an extraction. The condition was then to be treated with bone grafting to fill in the gap.

Process & Conclusion

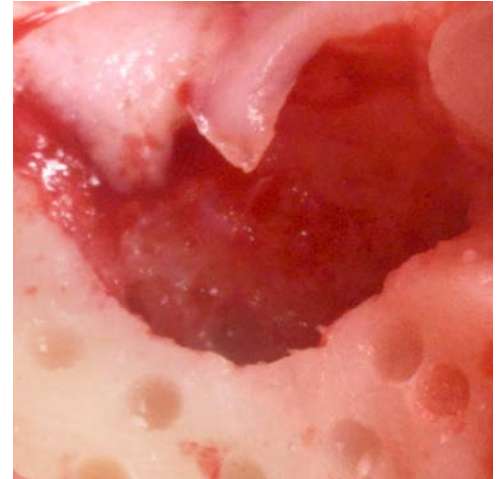
After the implant was extracted, the defect was filled with a mixture of InterOss® and autogenous bone. At re-entry, the cavity has been completely regenerated, enabling a new implant placement with a lasting stability even after 12 months.



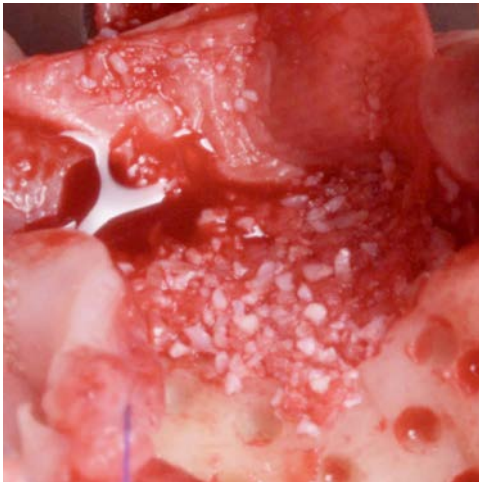Pre-operative view (note the pus discharge).



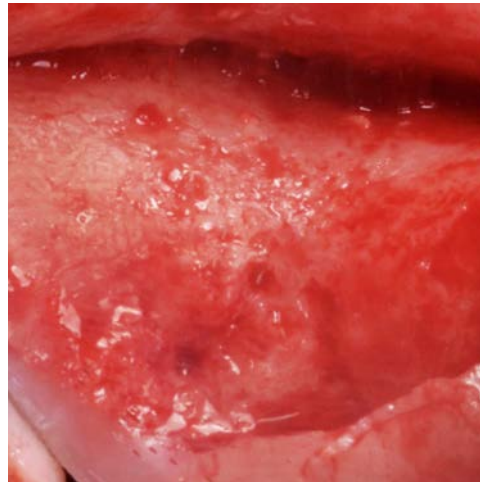
Pre-operative X-ray.



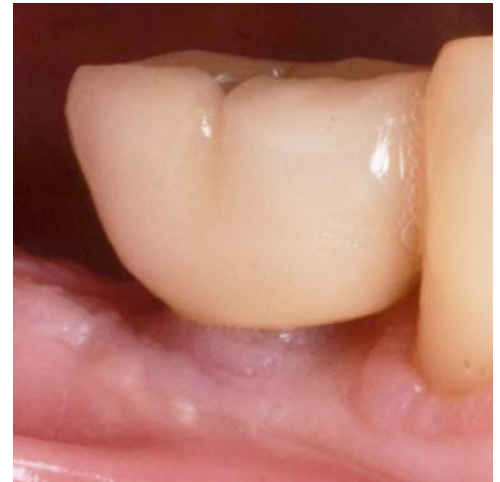Post-extraction view.



Placement of the InterOss® and autogenous bone mixture.



Re-entry view.



Post-loading view at 12 months.