



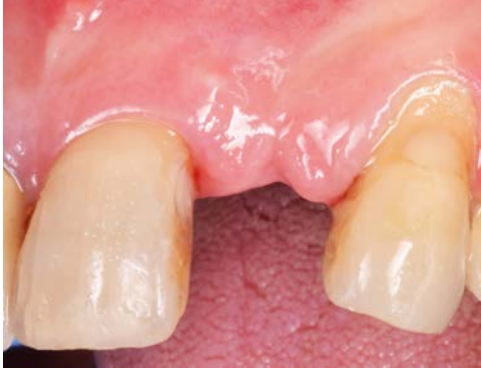# Implant placement in a deficient alveolar ridge in the anterior maxilla

## Patient History

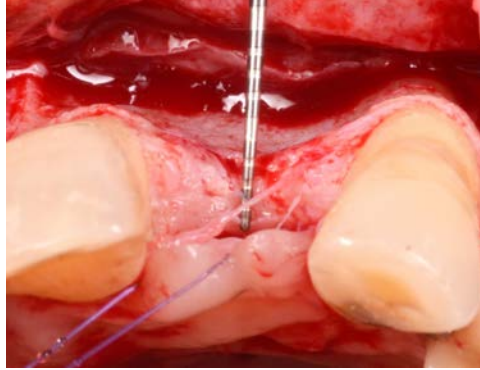
Patient had a missing tooth, and its absence has caused resorption to the affected bone. The condition was to be treated with an implant and bone grafting to gain back the space needed for the device.

## Process & Conclusion

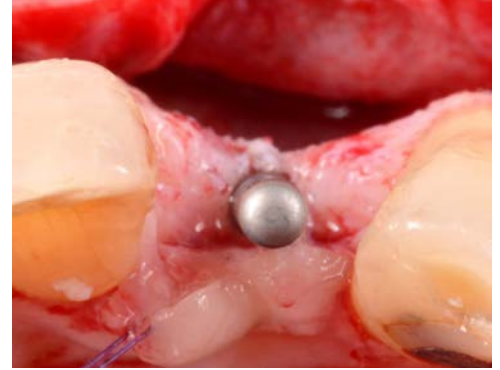After the implant is installed, InterOss® is placed in the gap of the bone defect and then wrapped with a collagen membrane. Follow-up at 1 year reveals a still solid bone surrounding the implant.



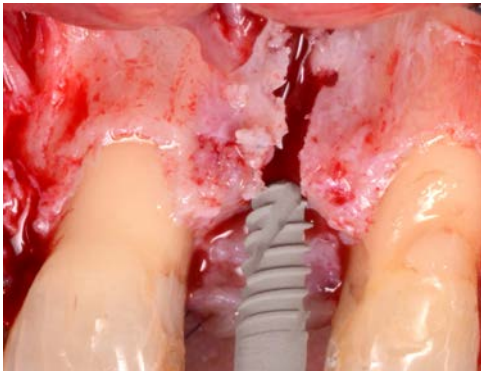
Pre-operative view.



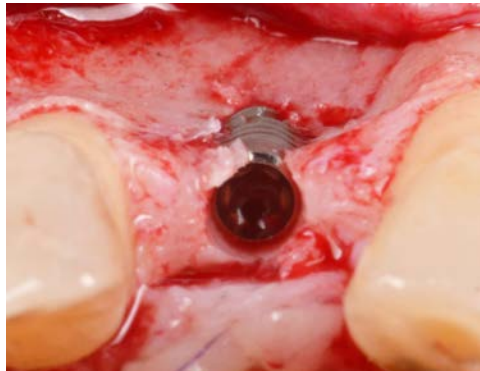
A view of the bone defect.



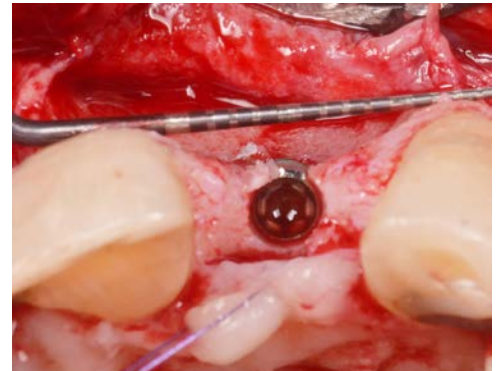
An osteotomy to prepare for implant placement.



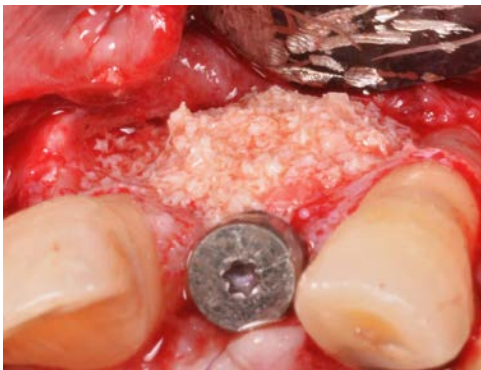Implant placement.



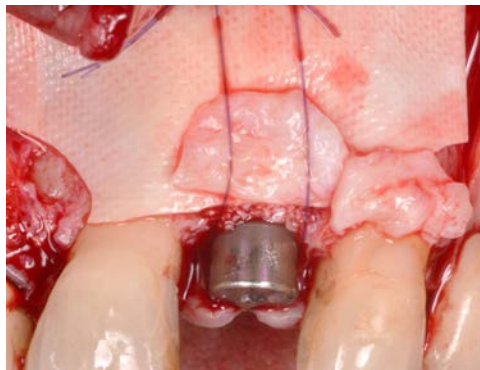
Post-loading view (note the bone deficiency).



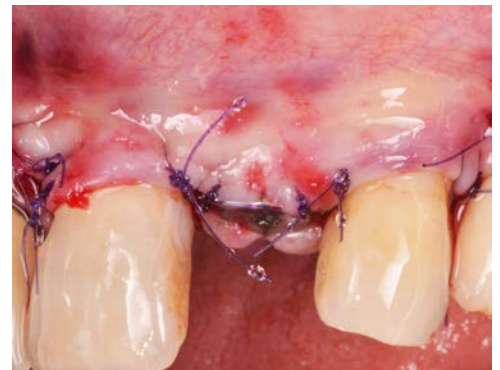A periodontal probe shows the lack of thickness.



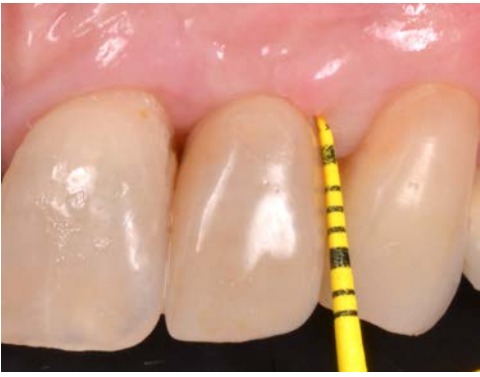InterOss® placement.



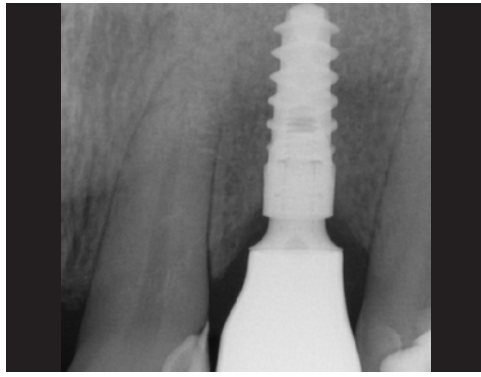
Membrane placement.



Post-surgical view.



Post-operative view at 1 year.



Post-operative X-ray at 1 year.