



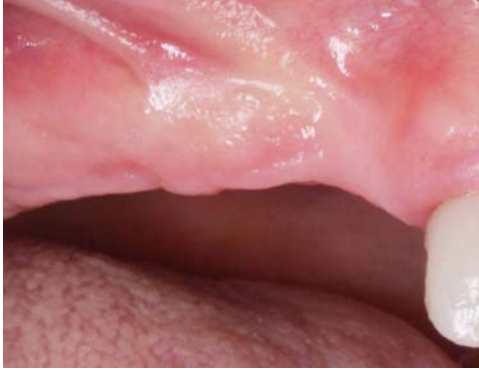Lateral ridge augmentation with simultaneous implant placement

Patient History

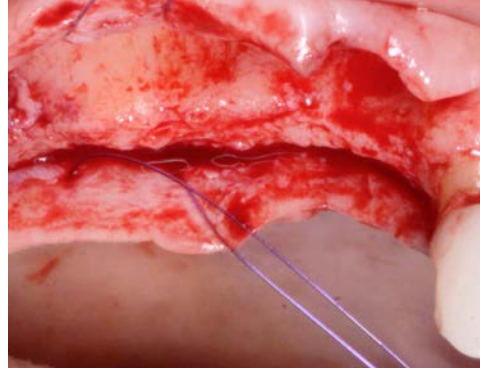
Patient had missing teeth at the posterior maxilla, and the devoid bone has undergone a resorption. The condition was to be treated with implants and bone grafting to restore the alveolar bone deficiency.

Process & Conclusion

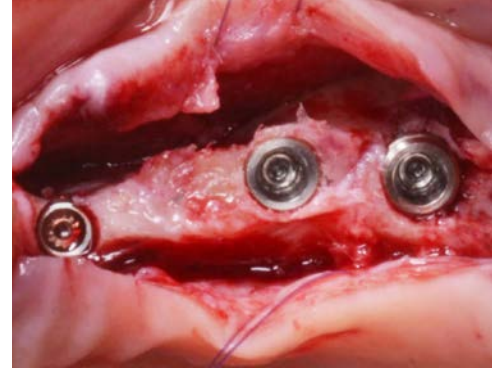
Implants were placed simultaneously with a GBR which entailed a contour augmentation in stratified layers in the atrophic maxillary ridge. Re-entry at 4 months revealed a complete reformation of the buccal bone thickness critical in preventing biological complications in the long-term.



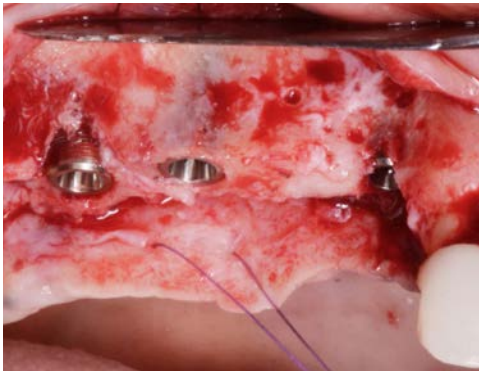
Pre-operative view.



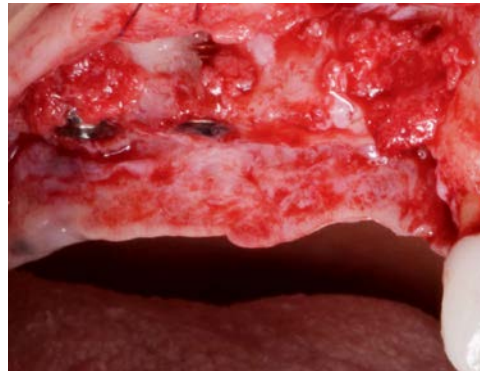A view of the bone defect.



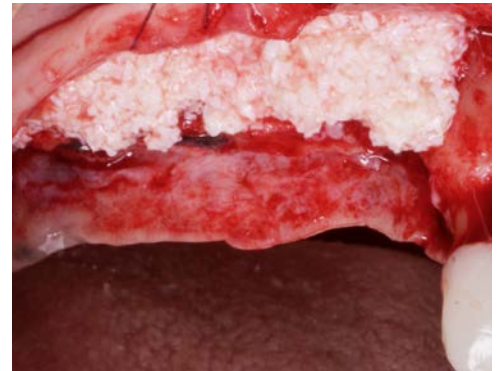Implant placement.



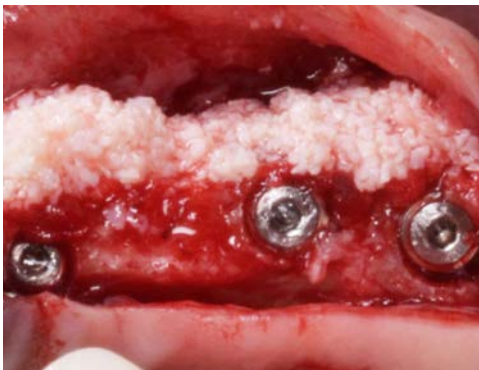A view of the installed implants (note the bone deficiency).



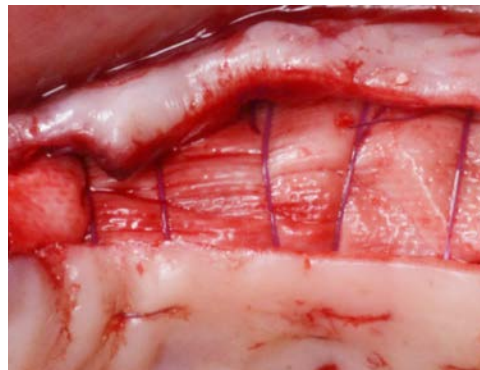Autogenous bone placement.



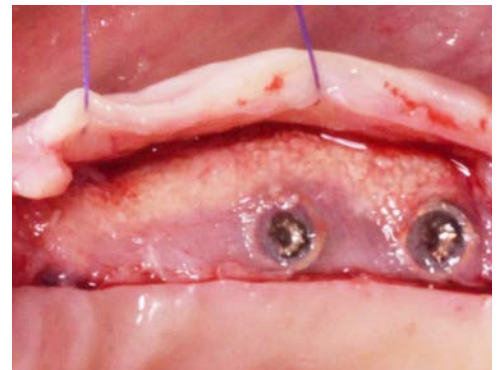InterOss® placement.



A view of the InterOss® granules on the ridge.



Collagen membrane placement.



Re-entry view at 4 months.