



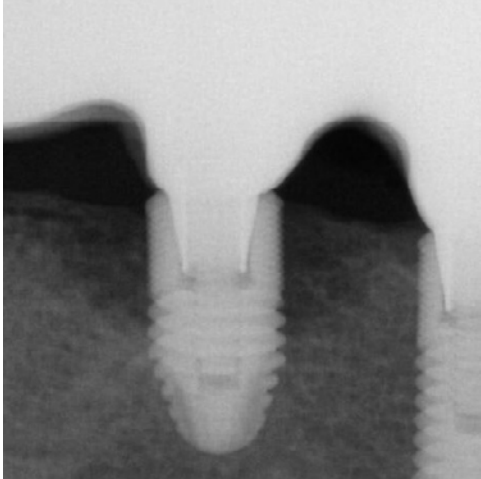
Alveolar ridge augmentation due to peri-implantitis

Patient History

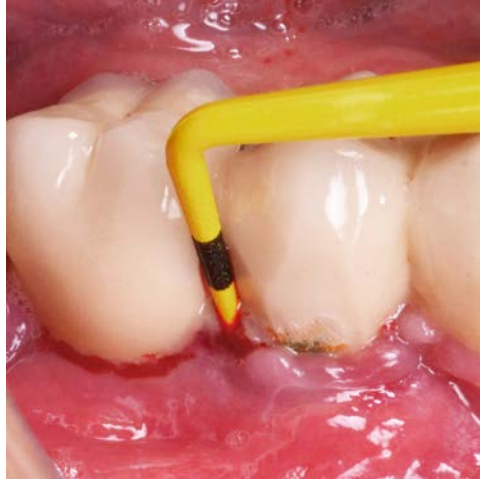
Patient suffered from a peri-implantitis with bone loss occurring all around the implant. The condition was to be treated with implantoplasty and bone grafting to fill in the gap.

Process & Conclusion

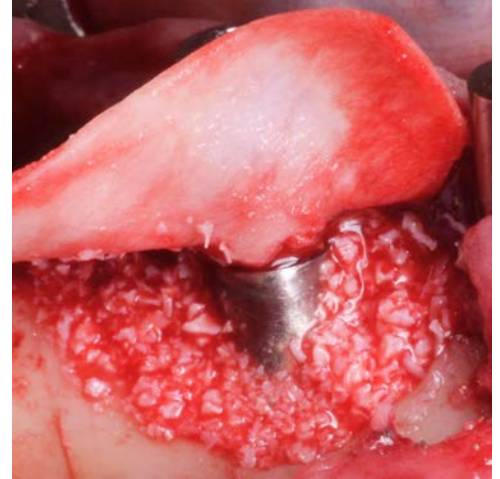After an implantoplasty was performed, the receding bone around the implant was filled with a mixture of InterOss® and autogenous bone. X-ray at 10 months shows new bone now surrounding the implant.



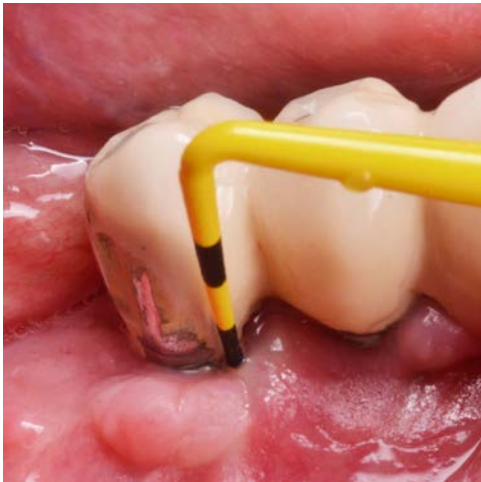Pre-operative X-ray.



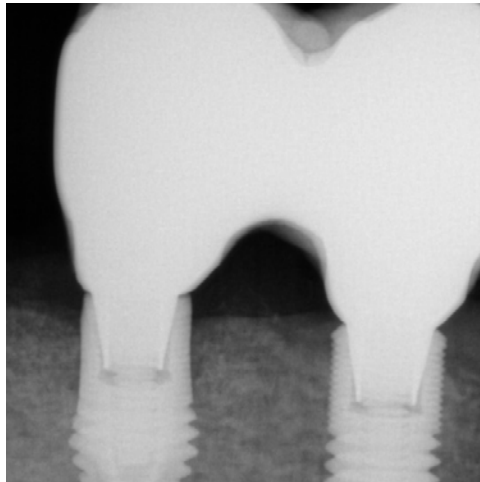
A periodontal probe shows the depth of the defect.



Placement of the InterOss® and autogenous bone mixture.



Post-operative view at 10 months.



Post-operative X-ray at 10 months.