



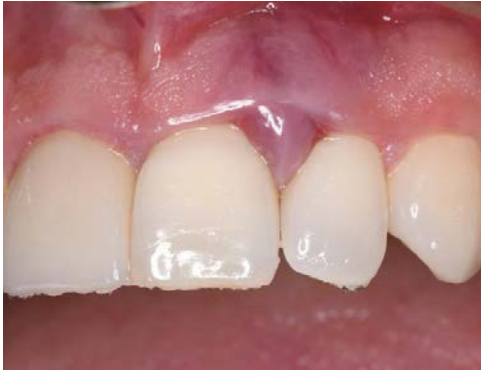# Guided tissue regeneration of an infrabony defect

## Patient History

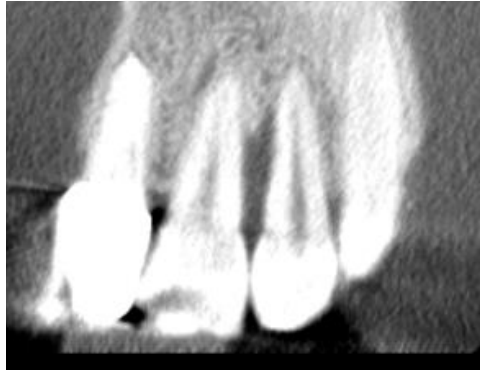
An infrabony defect had occurred in between the patient's tooth #9 and #10 with a pocket measuring as deep as 9 mm. The condition was to be treated with a guided tissue regeneration to fill in that pocket.

## Process & Conclusion

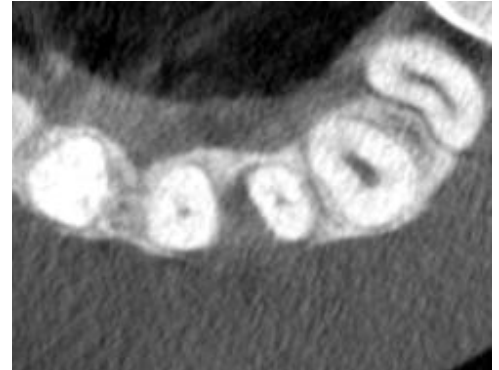After degranulation and debridement, the pocket was filled with InterOss® granules and wrapped with a collagen membrane. Radiographically, a very favorable bone gain can be observed, and the pocket was reduced to 3 mm. No adverse events attributed to InterOss® were recorded.



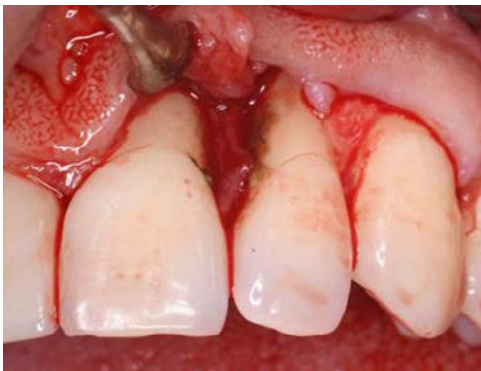Pre-operative view.



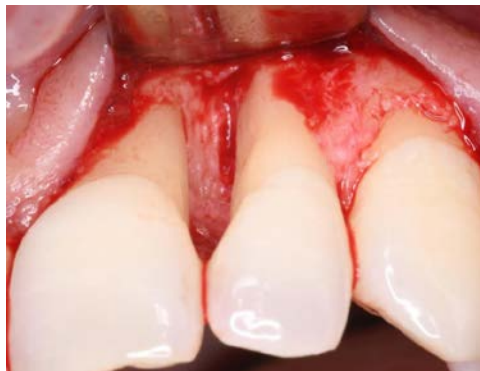Pre-operative CBCT scan.



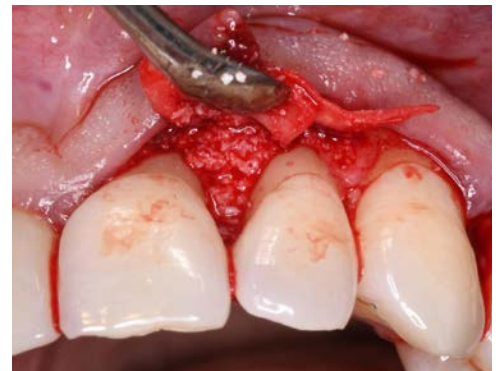Another pre-operative CBCT scan.



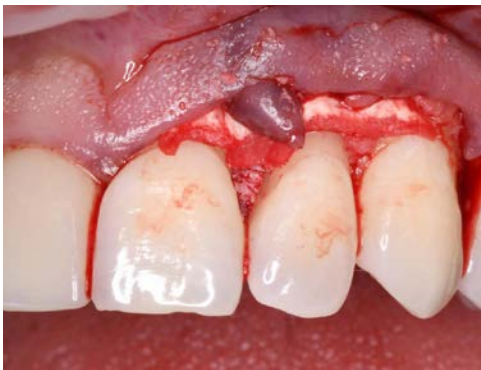A view of the bone defect.



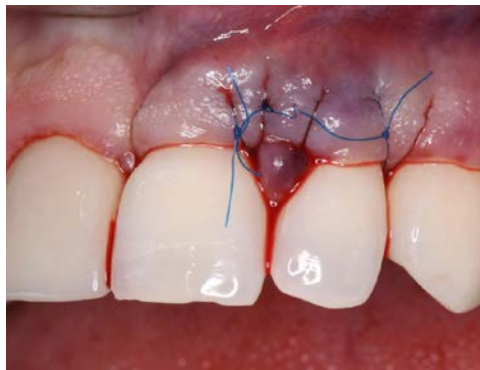Post-degranulation and debridement view.



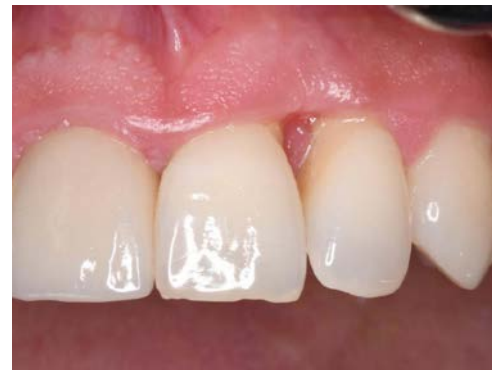InterOss® placement.



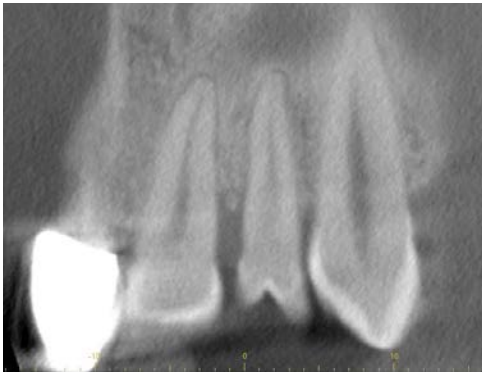
Collagen membrane placement.



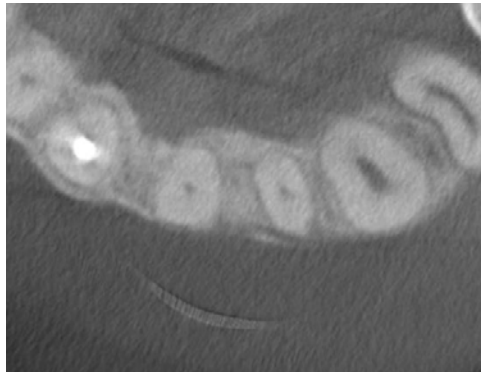Post-surgical view.



Post-operative view at 5 months.



Post-operative CBCT scan at 5 months.



Another post-operative CBCT scan at 5 months.