



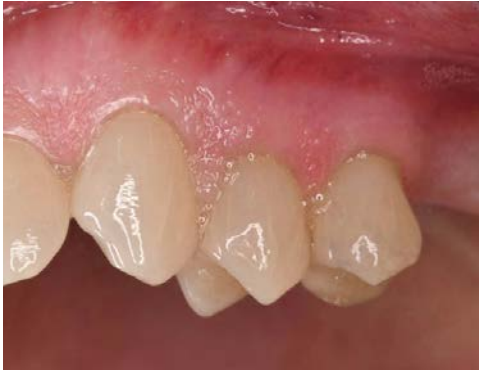# Immediate implant placement with simultaneous socket preservation

## Patient History

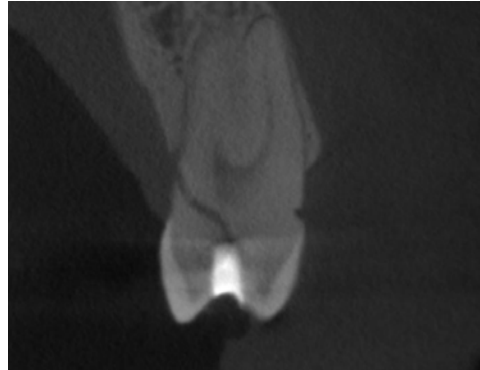
Patient suffered from a fractured premolar which required an extraction. The condition was then to be treated with an implant and bone grafting of the socket left by the extraction.

## Process & Conclusion

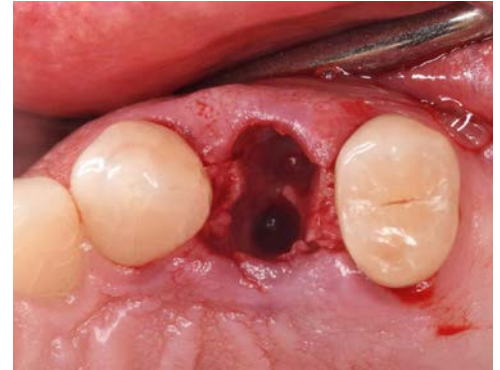After the tooth was extracted, an implant was placed immediately with the surrounding gap filled with InterOss®. Follow-up at 4 months showed successful healing without any complications.



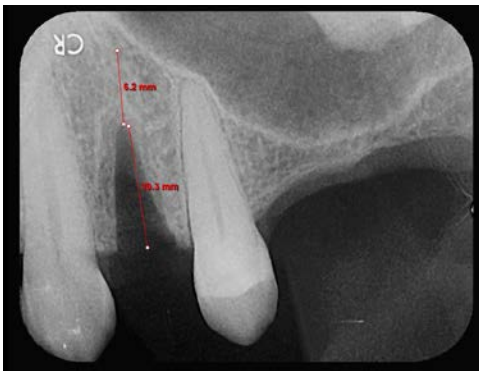Pre-operative view.



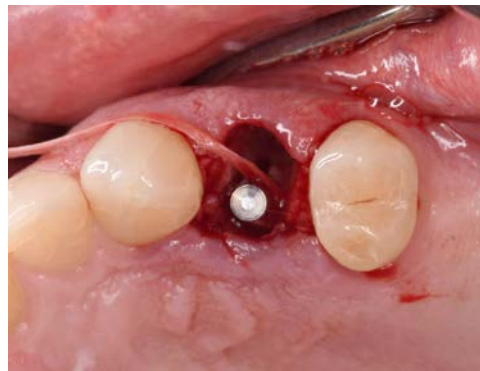Pre-operative CBCT scan.



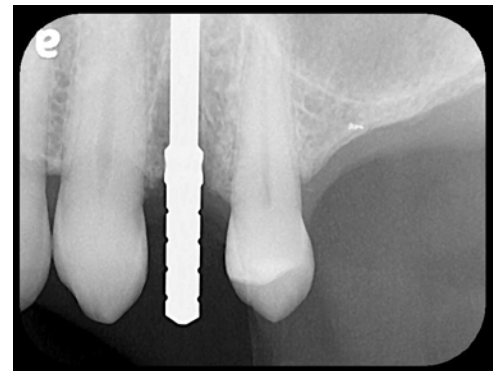
Post-extraction view.



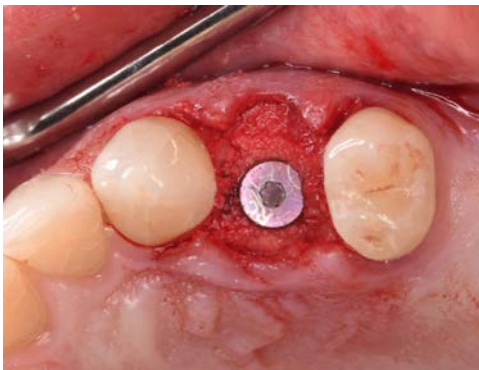
Post-extraction X-ray.



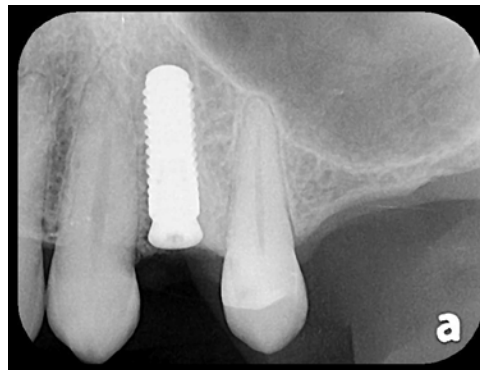
An osteotomy to prepare for implant placement.



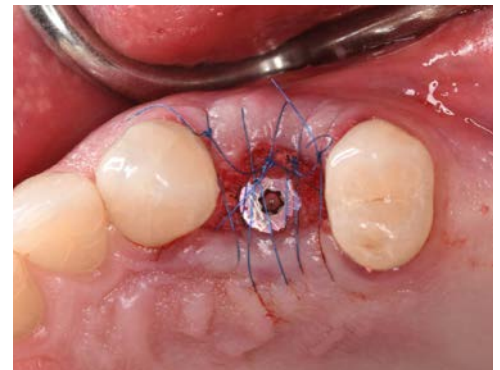Intra-osteotomy X-ray.



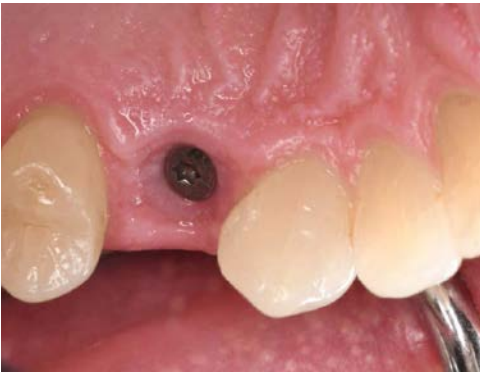Placement of implant and InterOss®.



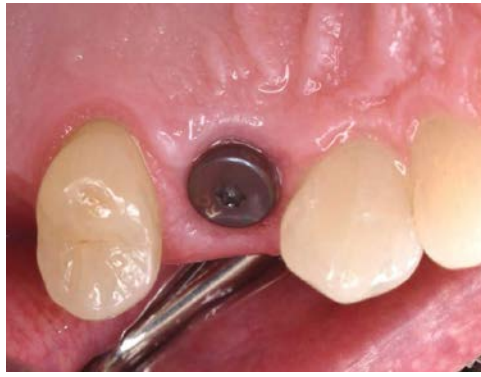Post-loading X-ray.



Post-surgical view.



Post-operative view at 6 weeks.



Post-operative view at 4 months.