



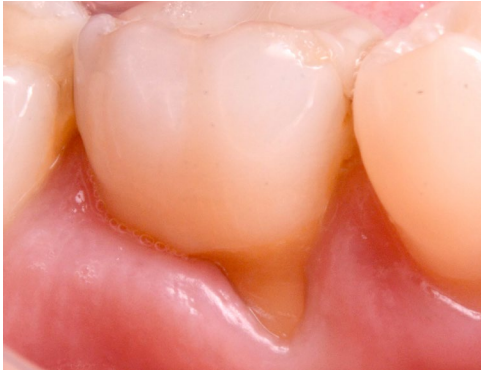# Immediate implant placement with simultaneous guided bone regeneration

## Patient History

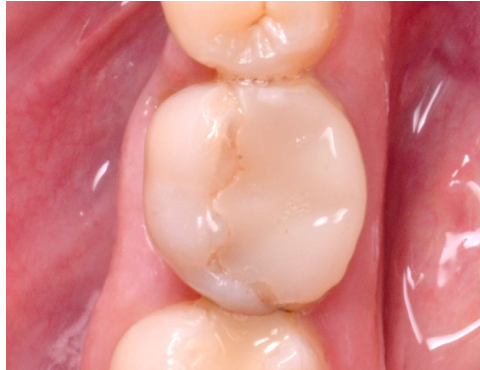Patient experienced a vertical root fracture in one of their molars which required an extraction. To replace the now missing tooth, an implant with simultaneous bone grafting was prescribed.

## Process & Conclusion

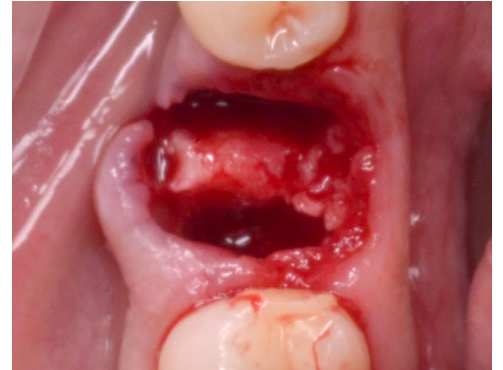After the affected tooth was extracted, an implant was installed immediately and the socket was filled with InterOss® granules. Follow-up at one year shows the implant is in stable condition as X-ray reveals it is surrounded by newly formed bone.



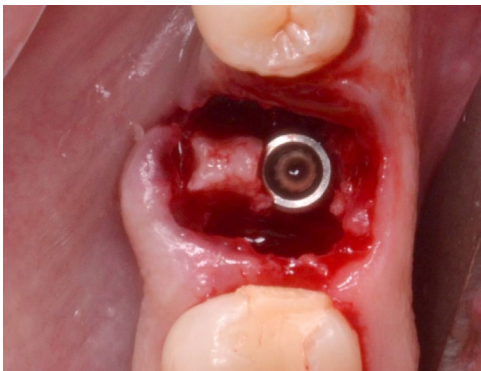
Pre-operative view.



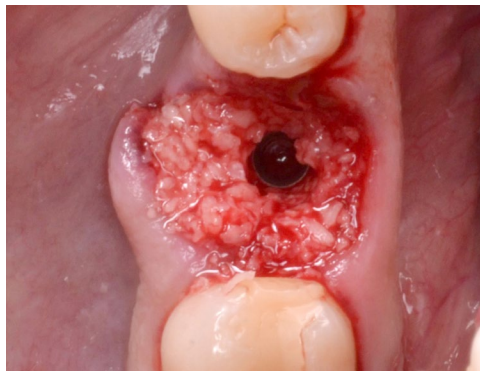
Another pre-operative view.



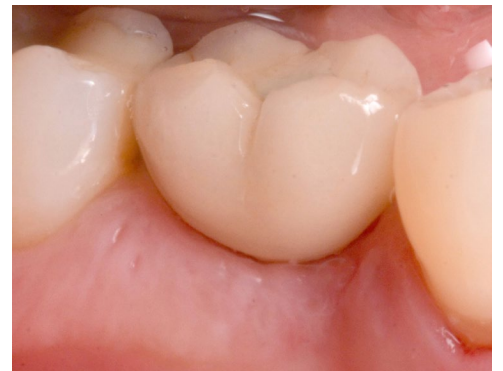Post-extraction view.



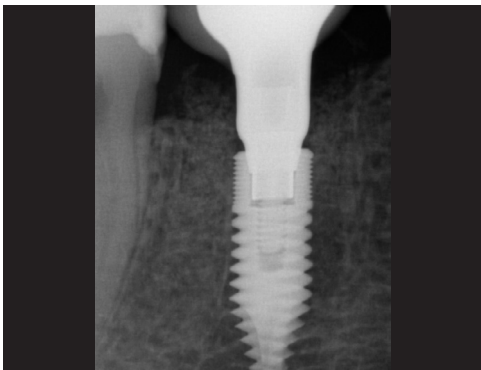
Implant placement.



InterOss® placement.



Post-operative view at 1 year.



Post-operative X-ray at 1 year.